

Nigerian Journal of Urology

The Official Publication of the Nigerian Association of Urological Surgeons
Volume 10 No. 1 & 2 (March and September) 2020

The Editorial Board of the Nigerian Journal of Urology

Editor-in-Chief
Prof AME Nwofor

Editors **Prof Ndu**
Eke Prof
O.B.Shittu Prof
J.C Orakwe Prof
V. Ramyil Prof. A
Essiet

Assistant Editor
Prof. C.K Oranusi
Prof. F Ugwumba

Editorial Advisers **Prof**
O.O.Mbonu Prof
S.N.C Anyanwu Prof
J.O.Esho
Prof C.A. Attah

Editorial Notices

The Nigerian Journal of Urology (NJU) is normally published twice a year in March and September.

Subscription

Members of the Nigerian Association of Urologic Surgeons receive the NJU as part of their membership subscription.

Non-Member Subscription

The annual subscription rate in Nigeria is ₦1,000.00 (post free). The annual subscription rate for the rest of the world is \$100 (post free). Cheques should be made payable to the Nigerian Journal of Urology and addressed to the Editor - in - Chief.

Correspondence

All correspondence including manuscripts for publication should be addressed to:

Professor AME Nwofor
Editor - in - Chief
Nigerian Journal of Urology
Department of Surgery Nnamdi
Azikiwe Teaching Hospital Nnewi,
Nigeria
Email : nigerian.j.urology@gmail.com

All Rights Reserved

No part of this publication may be reproduced, stored in retrieval system or be transmitted in any form or any means without the written permission of the Editor - in- Chief.

Instructions to Contributors

Papers selected for publication are based on merit and on the condition that they have not been published or submitted elsewhere for publication. The Editor does not necessarily agree with the views of the contributors and advertisers, they do not have legal responsibility for such views. Materials cited for publication will include scientific research papers read at the meetings of the Society and their abstracts as well as suitable papers. The Nigerian Journal of Urology, publishes original articles, special articles (by invitation), reviews, case reports, correspondence and notes.

Preparation of Manuscripts

Manuscripts (3 copies) should be clear, typewritten with double spacing on one side of the paper not longer than A4 (206x294). Manuscripts need not resemble closely the contribution to the meetings of the Society. Original Scientific Articles should consist of the following section:

Title page
Summary
Introduction
Patients and Methods
Results Discussion
Acknowledgement(s)
References

Tables
Legend to Figures

An electronic copy in Word format should be included at the time of submission.

Title Page

The title page should contain the following:

- (i) Title of the article which should be clear and concise.
- (ii) A title not exceeding 40 letters and spaces for uses as a nursing headline.
- (iii) The names and initials of author(s).
- (iv) The departments and institutions where the work was done and their address.
- (v) Name and correct address of Corresponding author.
- (vi) Keywords (not more than 5 words).

Abstract (Structured)

A structured abstract (of not more than 150 words) should be written on the second page of manuscript stating the objectives, methods, main results and major conclusions.

Figures and Tables

Only tables and figures that are essential should be submitted. Tables (3copies) should be numbered in Roman Numerals. Figures (3copies) should be expertly drawn and photographs should be black and white, glossy in camera-ready form. Unmounted photographs are welcome and should be numbered in Arabic numerals. Figures should be numbered lightly at the back, and the top end indicated. Legend to the figures should be typed on a separate sheet of paper.

References

Authors must submit only essential references and should not write works that they have read without stating that the source of the information is secondary. Reference quoted must be indicated by the numbers 1, 2 in the text and numbered and listed in the reference list consecutively. The abbreviated journal title should follow the style in the Index Medicus. Authors could be quoted in the text but if there are more than six, only the first six should be listed followed by et al. In the reference list, however, the names of all authors should be included. References should be as follows: author(s) name(s), title of paper, name of journal, year of publication, volume number, first and last pages, e.g.

Jaja S.J. Lung Function in Young Nigerian Adults. West Af. J. Med. 1991; 10: 262-285.

Reference to Book and Monographs

- (a) E.L. Farquharson Textbook of Operative 3rd ed. E. And S Living Edinburgh and London. 1996, 76-78.
 - (b) Moser H.W. Ceramidasee Deficiency in Standbury J. B. And Fredickson, D.S. The metabolic Basis of Inherited Diseases 4th ed. New Yark, McGraw Hill Book Company 1978; 702-710.
- Article in Press should not be cited.

Proofs

Corrected proofs should be sent back within 10 days.

Offprints/Reprints are not free. The sum of N 15, 000.00 will be charged for accepted manuscripts to cover page charges. Reprints may be ordered by the author before publication.

Units of Measurement

All measurement should be expressed in SI (Systeme Internationale) Units.

Acknowledgements

Only the assistance of those who contributed significantly in the study or the preparation of the paper (excluding secretariat assistance which is assured in all cases) should be acknowledged.

NIGERIAN JOURNAL OF UROLOGY

The Official Publication of the Nigerian Association of Urological Surgeons

Volume 10 No. 1 & 2 March - September 2020

Contents

Original Articles

Single Stage Buccal Mucosa Graft Urethroplasty for Long Segment Anterior Urethral Strictures: Experience and Outcome From A Tertiary Hospital

M Abdullahi 1

Comparison of Biochemical Efficacy of Bilateral Orchiectomy and Medical Castration (Goserelin) in Patients with Advanced Prostate Cancer at Lagos State University Teaching Hospital, Lagos

MO Omorinde, SO Ikuerowo, EA Jeje, OA Omisano, AA Abolarinwa 6

Prognostic Factors and Outcome of Treatment in Patients With Fournier's Gangrene in a Tertiary Institution in Nigeria

EA Obiesie, AME Nwofor, CK Oranusi, TU Mbaeri, OO Mbonu11

Efficacy of Urine Cytology in the Diagnosis of Bladder Cancer in Aminu Kano Teaching Hospital: Comparison of Cytology and Histological Findings

S Auwal, SU Alhassan, AA Sani, A Abdulkadir, AM Sharfuddeenhi, A Muzzammil, Y Bashir17

Review Article

Urinary Microbiome

TG Adedeji24

Case Reports

Premature Ejaculation: Response to Increasing the Frequency of Ejaculation. Report of a Case.

LI Okeke, CU. Okeke, OM Farinre, I Eze, HO Ekwuazi, SO Ogunlayi, AO Takure, SA Adebayo30

Abstracts

Abstracts Presented at the 22nd Scientific Conference & AGM of the Nigerian Association of Urological Surgeons (NAUS), Benin City, 2017.33

Single Stage Buccal Graft Urethroplasty for Long Segment Anterior Urethral Strictures: Experience and Outcome From A Tertiary Hospital.

M Abdullahi

Department of Surgery, Bayero University, Kano/Aminu, Kano Teaching Hospital, Kano, Nigeria.

DOI: 10.5281/zenodo.6569455

Abstract

Background: Urethral stricture is one of the common urologic diseases constituting significant workload to urology practice worldwide. The prevalence is estimated to be 229–627 per 100,000 males and its effects on the quality of life of those with the disease are enormous. Successful treatment of urethral stricture has been a challenge to urologists particularly long segment and complex strictures. This led to several procedures to evolve over past several decades. Substitution urethroplasty has become the gold standard procedure for the treatment of long segment anterior urethral strictures. **Objective:** To document the experience and outcome of use of single stage buccal graft urethroplasty for treatment of long segment anterior urethral stricture in a tertiary hospital. **Patients and Method :** It was a retrospective descriptive study of all patients who were treated for long segment anterior urethral stricture by single stage buccal graft substitution urethroplasty in our hospital from 2016 to 2021(5years). Medical records of patients were retrieved and their information about bio-data, presentation, risk factors for urethral stricture, investigations done. The type of buccal graft harvest and onlay and outcome including complications were extracted and entered into the already designed proforma. The generated data was entered into excel sheets and analyzed using special package for social sciences (SPSS) and results presented in tables and figures. **Results:** A total of 45 patients were treated for long segment anterior urethral stricture by single stage buccal graft substitution urethroplasty between 2016 and 2021(5years) of which the records of 42 patients were retrieved and data was collected and analyzed. All were males within the age range of 35 to 78 years and a mean age of 57.2years \pm 7.4SD. The risk factors for urethral stricture were past history of purulent urethritis (59.5%), prolong catheterization (21.5%), urethral trauma (9.5%), past urethral surgery (9.5%). The site of the urethral stricture was found as follows; Penile urethra (61.9%), Penobulbar (26.2%), Bulbar urethra (7.1%) and Panurethra (4.8%). Intra operative length of the stricture was found as follows: <5cm (21.4%), 5-10cm (23.8%), 10 -15cm (50%) and >15cm (4.8%). The buccal graft onlay procedures used were dorsolateral onlay (73.8%), dorsal onlay (14.3%), ventral onlay (11.9%). Following urethroplasty catheter was removed as follows: <4weeks (42.9%), 4-6weeks (38.1%) and >6weeks (19%). Complications recorded were: Surgical site infection (21.4%), urethral diverticulum (4.8%), urethrocutaneous fistula (2.4%) and recurrence (4.8%). Majority of the patients (66.7%) had no complication. **Conclusion:** Single stage buccal graft substitution urethroplasty for long segment anterior urethral stricture has overall good success rate with minimal complications.

Keywords : Single stage, Buccal graft, Long segment urethral stricture

Address for Correspondence:

Dr Muzzammil Abdullahi

Department of Surgery, Bayero University, Kano

E-mail: muzzammilabdullahi77@gmail.com

Introduction

Urethral stricture is one of the common urologic diseases constituting significant workload to urology practice worldwide. The prevalence is estimated to be 229–627 per 100,000 males and its effects on the

quality of life of those with the disease are enormous¹. In Sub-Saharan Africa, the incidence is probably higher, due to the higher prevalence of poorly treated urethritis in addition to other aetiologies². Early reports almost completely attributed urethral stricture to gonococcal urethritis. However, several other causes have been identified and they include trauma, iatrogenic, post hypospadias repair, lichen sclerosis, post prostatectomy, radiotherapy, and catheter induced. Whereas trauma and iatrogenic causes are commonest in developed countries, inflammatory causes have now become infrequent¹, while in developing countries the inflammatory causes are still frequent². The management of the disease has evolved all over the world though not uniformly. A good history and physical examination contribute immensely to the diagnostic process. Retrograde urethrography (RUG) remains the gold standard investigation, while urethrosography, computerized tomography (CT), and magnetic resonant imaging (MRI) are presently seen as adjunct to RUG³. Successful treatment of urethral stricture has been a challenge to urologists particularly long segment and complex strictures. This led to several procedures and their evolution over several decades. Open surgical repair using grafts or flaps, called substitution urethroplasty, has become the gold standard procedure for anterior urethral strictures that are not amenable to excision and primary anastomosis (long segment and complex strictures)⁴. Oral mucosa harvested from the inner cheek (buccal mucosa) is an ideal material, and is most commonly used for substitution urethroplasty, the use of buccal mucosa was first described in 1941^{4,6} and reintroduced in 1992^{4,6}. It possesses the advantages of constant availability, easy harvesting, favorable immunological properties (resistance to infection) and good tissue characteristics (a thick epithelium, high content of elastic fibers, thin lamina and rich vascularization). Onlay augmentation on the ventral side (ventral onlay) or dorsal side (dorsal onlay, Barbagli procedure) has been widely used for bulbar urethral stricture with comparable success rates. Most penile urethral strictures can be repaired in a one-stage procedure either by dorsal inlay with ventral sagittal urethrotomy (Asopa technique) or dorsolateral onlay with one-sided urethral dissection (Kulkarni technique); however, staged urethroplasty remains the procedure of choice for complex strictures, including strictures associated with genital lichen sclerosis or failed hypospadias^{1,4}. We undertook a retrospective study to document the experience and outcome of single stage buccal graft

urethroplasty for patients managed for long segment anterior urethral stricture in a tertiary hospital.

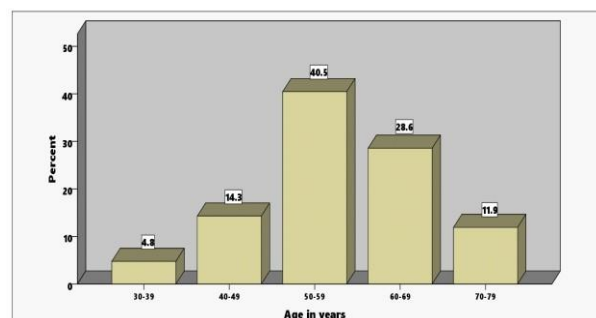
Patients and Method

It was a retrospective descriptive study of all patients who were treated for long segment urethral stricture by single stage buccal graft substitution urethroplasty in our hospital from 2016 to 2021(5years). Ethical approval was obtained from the research and ethics committee of the hospital for the conduct of the study. Particulars of the patients who had the procedures over the period covered by the study were retrieved from the theatre register and their medical records were collected with the help of the record staffs of the hospital. Information about the patients' bio-data, presentation, risk factors for urethral stricture, investigations done, the type of buccal graft harvest and onlay and outcome including complications were extracted and entered into the already designed proforma. The generated data was entered into excel sheets and analyzed using special package for social sciences (SPSS) and results presented in tables and figures.

Results

A total of 45 patients were treated for long segment anterior urethral stricture by single stage buccal graft substitution urethroplasty between 2016 and 2021(5years) of which the records of 42 patients were retrieved and data was collected and analyzed. All were males within the age range of 35 to 78 years and a mean age of 57.2years \pm 7.4SD, the age distribution is shown in Fig 1.

Figure 1: Age distribution of the patients



Past history of purulent urethritis is the most common risk factor for urethral stricture among our patients as shown in Figure 2

The site of the urethral stricture was found as follows;

Penile urethra (61.9%), Penobulbar (26.2%), Bulbar urethra (7.1%) and Panurethra (4.8%). Intra operative length of the stricture estimated to ascertain the length of the graft to be used was found as follows: <5cm (21.4%), 5-10cm (23.8%), 10-15cm (50%) and >15cm (4.8%). Different buccal graft onlay procedures were used depending on the site of the stricture as shown in Table 1.

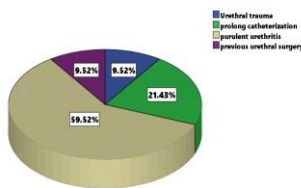


Figure 2: Risk Factors for Urethral Stricture

Table 1: Buccal Graft Onlay Procedures

Buccal graft onlay procedure	Frequency	Percent
Dorsal onlay	6	14.3
Dorsolateral onlay	31	73.8
Ventral onlay	5	11.9
Total	42	100.0

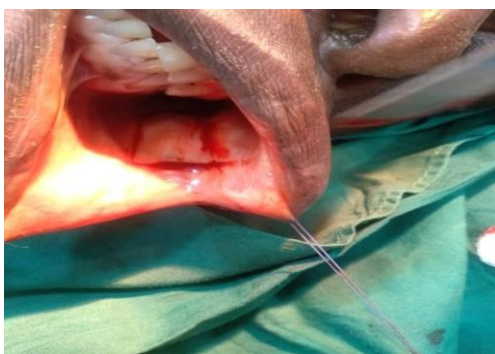

Figure 3: Harvesting Buccal Graft

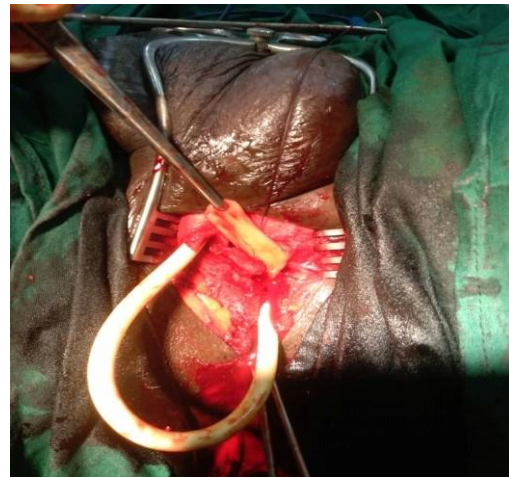


Figure 4: Urethra lay open with the graft

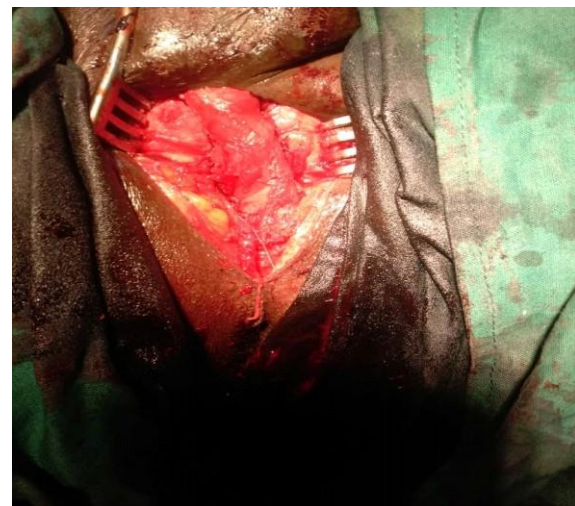

Figure 5: Urethra after Reconstruction

Table 2: Complications of Single Stage Buccal

Graft Urethroplasty

Complications	Frequency	Percent
Surgical site infection	9	21.4
Urethral diverticulum	2	4.8
Urethro-cutaneous fistula	1	2.4
Recurrence	2	4.8
None	28	66.7
Total	42	100.0

Figure 3, 4, and 5 below shows an intraoperative buccal graft harvesting, urethral layered open with the graft and urethral after reconstruction respectively. The duration of urethral catheter was based on satisfactory healing with no evidence of contrast leakage on peri-catheter RUG as follows: <4weeks (42.9%), 4-6weeks (38.1%) and >6weeks (19%). Few complications were recorded among our patients who were followed up for a period between 6-12months post surgery. Majority had good outcome as shown in Table 2.

Discussion

The mean age of our patients is 57.2years \pm 7.4SD which is similar to finding from a study with larger sample size from the same region⁷. The risk factors for urethral stricture in our patients are largely previous urethritis and previous catheterization. These risk factors are known to predispose patients to have long segment urethral stricture which all the patients had. This further explains why most of the strictures were found at the penile and peno-bulbar region of the urethra^{2,3}. The findings are similar to those from other studies^{8,9}.

The length of the stricture in more than half of our patients was greater than 10cm; this differs from findings in other studies done in Asia^{10,11} which found most stricture length between 5-8cm. This could be explained by the different aetiologies of the stricture. Dorsolateral buccal graft onlay was used in majority of patients owing to site of most of the strictures and being simple to perform with good results in previous studies¹¹. The catheter was removed in less than 6weeks for most patients, however it was prolonged in few patients due to delayed healing as evidenced by contrast leakage on peri-catheter RUG. Successful

urethroplasty evidenced by non recurrence of the stricture after 6-12months was achieved in more than 80% of the patients; this is also similar to findings from other studies¹²⁻¹⁵.

Conclusion

The use of single stage buccal graft substitution urethroplasty for long segment anterior urethral stricture has overall good success rate with minimal complications.

Acknowledgement

Special thanks to Dr Ahmad Sani, registrar at the Department of Surgery, Aminu Kano Teaching Hospital(AKTH), Kano for retrieving patient information from operating theatre register and to staff of Department of records, AKTH for retrieving the medical record of patients.

References

1. Eshioho I, Eghosa A, Quincy A, Emmanuel E. Aetiology And Evaluation Of Men With Urethral Stricture And The Current Role Of Urethroplasty In The Treatment Of Anterior Urethral Strictures. *EMJ Urol*. 2018; 6[1]:82-89.
2. Irekpita E, Udefiagbon . A Review of the Epidemiology and Management of Urethral Stricture Disease in Sub-Saharan Africa. *Current Medical Issues* 2019; 17:118-124.
3. Joshua A B, Bradley F S et'al. Urethral Strictures in Males. www.medscape.com 2018.
4. Akio H. Substitution urethroplasty using oral mucosa graft for male anterior urethral stricture disease: Current topics and reviews. *International Journal of Urology* 2017; 24(7):493-503.

-
5. Barbagli G, Balà S, Sansalone S, Lazzeri M. Dorsal onlay graft bulbar urethroplasty using buccal mucosa. *African Journal of Urology* 2016;22:5–10.
 6. Shariful Islam MD, Asaduzzamman MD, Kaiser A, Salam MA, Shawkatalam MD Outcome Of Single Stage OMG. Urethroplasty By Kulkarni Technique In Comparison With Johanson's Staged Urethroplasty For Management Of Pan-Urethral Stricture. *Bangladesh J. Urol.* 2016; 19(2):78-84.
 7. Ajape AA, Kuranga SA, Kura MM, Olanipekun HB. Autologous buccal mucosa harvest under local anesthesia: Feasibility, safety, and acceptance for substitution urethroplasty. *Urol Ann* 2019; 11:298-303.
 8. Eshioho I, Ehizomen E, Omosofe F, Onuora V. Buccal mucosal graft urethroplasty for proximal bulbar urethral stricture: A revisit of the surgical technique and analysis of eleven consecutive cases. *Niger Med J* 2016;57:266-71.
 9. Idorenyin CA, Samaila IS, Chima GO, Ayodele OS, Nuhu KD, Venyir MR. Dorsal onlay buccal mucosal graft urethroplasty for bulbar urethral stricture; a single centre experience. *Pan African Medical Journal* 2020; 36:305.
 10. Yidong L, Likai Z, Weijing Y, Ping P, Ming W. One-stage dorsal inlay oral mucosa graft urethroplasty for anterior urethral stricture. *BMC Urology* 2014, 14:35.
 11. Vikram P, Shishir D., Ritesh V., Murigendra H. Single stage: dorsolateral onlay buccal mucosal urethroplasty for long anterior urethral strictures using perineal route *IBJU Int. n braz j urol* 2016; 42 (3) : .
 12. Ujwal Kumar, N.K. Jha. Dorsal onlay substitution urethroplasty using buccal mucosa and penile skin grafts - our experience. *International Journal of Contemporary Medical Research* 2019; 6(7):G1-G4.
 13. Felix C., Simon B., Mariya D., Anastasia V F, Stella L I, and Daniela E A, et' al. Single-stage tubular urethral reconstruction using oral grafts is an alternative to classical staged approach for selected penile urethral strictures. *Asian J Androl.* 2020;22(2):134–139.
 14. Ngwobia PA, Ahmed MU. Practice of the use of oral mucosa graft urethroplasty among Nigerian urologists.. *Int Surg J.* 2020 May; 7(5):1351-1356.
 15. Winston M, Christian AA. One-Stage Urethroplasty for Strictures at a Rural Hospital. *Ann Afr Surg.* 2019; 16(1):16–19.